Hind AlMaghthawi et al, 2018;1(1):47–50.
https://doi.org/10.24911/JBCGenetics/183-1532438227

CASE REPORT

Epileptic encephalopathy caused by biallelic mutation in *PPM1D*: a case report

Hind AlMaghthawi[1,2], Marwan Nashabat[1], Majid Alfadhel[1]*

ABSTRACT

Background: *PPM1D* gene encodes for metal-dependent protein phosphatase. Its function includes the inhibition of some tumor suppressor genes, DNA damage response, and cell cycle control. Germline heterozygous *de novo* mutations in this gene were reported to cause intellectual disability and hypotonia.

Case Presentation: We report a 40-month-old girl with an intractable seizure disorder, microcephaly, and global developmental delay. She had frequent epileptiform discharges on electroencephalography. Molecular investigations showed a homozygous truncating mutation in the *PPM1D* gene. Both parents were healthy heterozygous carriers.

Conclusion: This is the first time in the literature to describe a homozygous biallelic mutation in the *PPM1D* gene, which resulted in epileptic encephalopathy, microcephaly, and global developmental delay. *PPM1D* mutations could be inherited as autosomal recessive with asymptomatic heterozygote carriers.

Keywords: *PPM1D*, phosphatase, epileptic encephalopathy, intellectual disability.

Introduction

Thousands of phosphatases play variable roles in living cells. Among these is a family named haloacid dehalogenases (HAD) superfamily. The core function generally for all phosphatases is to dephosphorylate and consequently deactivate other proteins. HAD-superfamily phosphatases are characterized by a unique structure of their active site, which makes them less sensitive to phosphatase inhibitors (1). One type of HAD phosphatase is called serine/threonine-directed phosphatase, metal-dependent or serine / threonine-directed phosphatase, metal-dependent (PPM) represented by Protein phosphatase 2C (PP2C), which are dependent on manganese/magnesium ions and contain their catalytic and regulatory domain on one polypeptide (2). Protein phosphatase 1D (*PPM1D*) is one of these metal-dependent phosphatases.

The *PPM1D* was discovered to have variable functions including the inhibition of some tumor suppressor genes like P53 in the cellular stress response (3) and DNA damage response (4). Additionally, it has a role in the cell cycle regulation (5).

Previous studies reported an association between *PPM1D* and certain types of cancer where the gene was found mutated in somatic cells (6). The reported germline mutations were found to result in autosomal dominant intellectual disability syndrome (7). These patients were also found to have facial dysmorphic features, small hands and feet, a broad-based gait, hypotonia, and a high threshold to pain (7).

In this report, we describe the first case in the literature having a biallelic truncating mutation in the *PPM1D* gene behaving as autosomal recessive.

Case Presentation

A 40-month-old girl, a product of preterm pregnancy, delivered at 34 weeks of gestation via cesarean section due to prolonged rupture of membrane (Figure 1). She is the only child to double first cousin Saudi parents. Pregnancy was unremarkable with normal antenatal fetal ultrasound. Birth growth parameters were as follows: Weight by weight 1,400 g (<5th percentile) and head circumference 31 cm (<5th percentile). She stayed in the nursery for 6 weeks because of low birth weight, prematurity, and neonatal jaundice.

Correspondence to: Majid Alfadhel
*Division of Genetics, Department of Pediatrics, King Saud bin Abdulaziz University for Health Sciences, King Abdulaziz Medical City, Riyadh, Saudi Arabia.
Email: dralfadhelm@gmail.com
Full list of author information is available at the end of the article.
Received: 12 November 2017 | **Accepted:** 22 December 2017

© Author(s) open access CC BY

This is an open access article distributed in accordance with the Creative Commons Attribution (CC BY 4.0) license: https://creativecommons.org/licenses/by/4.0/)

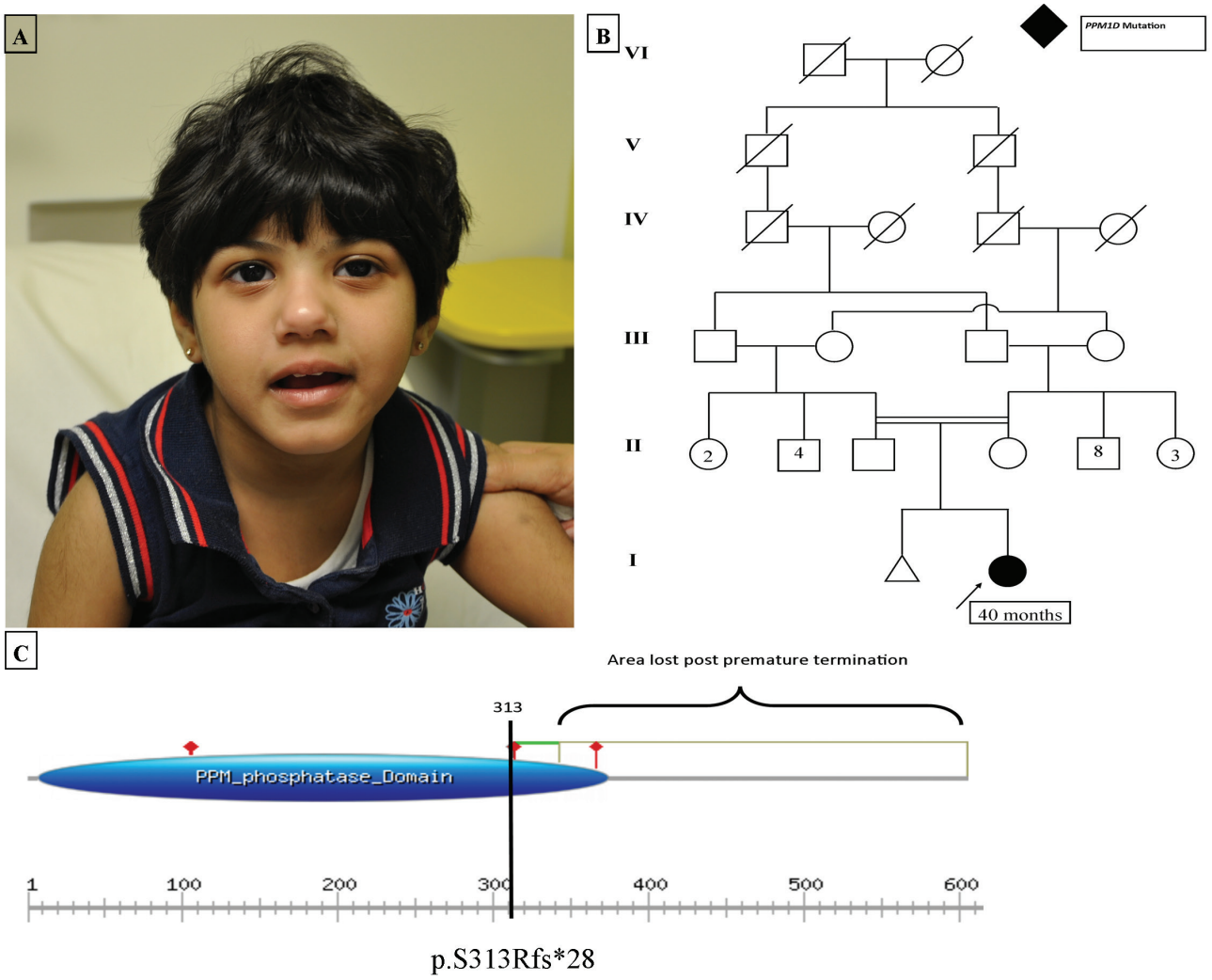

Figure 1. *(a) Patient with PPM1D biallelic mutation showing microcephaly, triangular face, and hirsutism. (b) Family pedigree. Parents are first double cousins. The patient is the only affected in the family. (c) PPM1D protein showing the PPM phosphatase domain. The variant creates a shift in the reading frame starting at codon 313. The new reading frame (green) ends in a stop codon 27 positions downstream. Red arrows represent the site of metal binding at positions 105, 106, 314, and 366, respectively (14).*

She was doing well until 7 months of age when she developed focal seizure involving the left side of the body. She was having global developmental delay and failure to thrive. She was started initially on two antiepileptic medications (phenobarbital and carbamazepine) with partial control. She had laryngomalacia, mild gastroesophageal reflux disease in addition to the sustained failure to thrive, which required gastrostomy tube for feeding. She had a sleep disturbance. However, there was no ophthalmological or auditory problem or a behavioral abnormality. Although she had a high pain threshold during intravenous (IV) cannulation which seemed to fade as the baby got older. She began recall names and attempted to crawl at the age of 30 months and she walked at the age of 38 months.

Currently, her height is 92 cm (10th–25th percentile), weight 12 kg (10th–25th percentile), and head circumference 41 (<3rd percentile). Her seizure is still refractory requiring four antiepileptic medications (Phenobarbital, carbamazepine, lamotrigine, and clonazepam). She is still having a speech delay. She has brachycephaly and microcephaly, triangular face, and hirsutism with no apparent skeletal deformity. Other systemic examination was unremarkable. Electroencephalography (EEG) showed frequent epileptiform discharges. The magnetic resonance imaging (MRI) brain was for her age. Ultrasound abdomen showed right-sided dysplastic kidney and left kidney compensatory hypertrophy with mild left renal pelvic dilatation. There was abnormal middle ear function initially suggestive of possible middle ear fluids, bilaterally with normal cochlear function and normal hearing sensitivity. Extensive biochemical workup was done but all were unremarkable.

Genetic investigations starting with karyotype, genomic comparative hybridization were all unremarkable.

Microcephaly gene panel was unremarkable as well. Whole exam sequencing was done for the patient and parents and revealed a pathogenic homozygous missense variant on the *PPM1D* gene (NM_003620) in exon 4 c.938_939delGT (p.S313Rfs * 28). Both parents are a heterozygotes carrier.

Discussion

Germline mutations in the *PPM1D* gene were reported only once in the literature among Jansen et al. (7) series. Intellectual disability was the common feature among all the reported patients. However, the patients had other associated features. The current patient had some common features with other reported patients like microcephaly, hypotonia, intellectual disability, characteristic facial features, feeding difficulty, laryngomalacia, and a high threshold to pain. However, her patient's neurological manifestations were more severe than the previous patients. She had intractable seizures with multiple epileptiform discharges on EEG, which was not reported previously.

This is the first time in the literature to report a biallelic truncating mutation in the *PPM1D* gene. The mutation described in the current patient was in exon 4 and resulted in more truncation in the protein in comparison with the mutations reported previously. Furthermore, the mutation results in the early termination codon after which the site of cofactor binding (magnesium/manganese) will be lost (Figure 1c). The homozygosity and the nature of the mutation may explain the severity of the patient's neurological symptoms.

All the previously reported mutations were *de novo*, however, the current patient inherited the mutation from her parents, who were heterozygous carriers for the mutation, yet they were completely healthy. This finding may broaden the mode of inheritance of *PPM1D* gene mutations to include autosomal recessive in addition to the previously reported autosomal dominant pattern. The observation of recessive mutations in known autosomal dominant genes has been reported previously in Saudi populations (8).

Other related types of protein phosphatases were correlated with epileptic encephalopathy. For example, polynucleotide kinase phosphatase (PNKP), another phosphatase that contains a phosphatase domain similar to HAD phosphatases (9). Homozygous mutations in PNKP were previously linked to early infantile epileptic encephalopathy type 10 with microcephaly, epilepsy, and developmental delay (10,11).

The proband's phenotype fulfills the definition of the epileptic encephalopathy by the International League Against Epilepsy which stated that "the epileptic activity itself may contribute to severe cognitive and behavioral impairments above and beyond what might be expected from the underlying pathology alone (e.g., cortical malformation), and that these can worsen over time" (12). Although the patient had normal brain MRI, she had a severe intractable seizure and global developmental delay. She underwent a series of EEGs, which tend to worsen with time.

Many of the previous studies and reports focused on the implication of *PPM1D* in different types of cancers like ovarian, colon, breast, and others (6,13). All these studies described mutations in somatic cells only. None of the patients reported to have germline mutations in *PPM1D*, including the current patient and Jansen et al. (7) series were reported to develop any type of cancers so far. However, it might be wise to keep in mind the association of this gene with malignancy and to monitor the patients regularly until future studies confirm or repeal that association.

To conclude, this is the first time in the literature to describe a homozygous biallelic mutation in the *PPM1D* gene, which resulted in epileptic encephalopathy, microcephaly, and global developmental delay. *PPM1D* mutations could be inherited as autosomal recessive with asymptomatic heterozygote carriers. Finally, there is no proof so far of the association of *PPM1D* germline mutations and malignancy. Further studies and prospective cohorts are needed to delineate more the phenotype of *PPM1D* mutation.

Acknowledgement
We are grateful to the patient and her family reported in this article for their genuine support.

List of abbreviations

EEG: Electroencephalography; HAD: haloacid dehalogenases;
ILAE: International League Against Epilepsy;
IV: intravenous;
MRI: Magnetic Resonance Imaging;
PNKP: polynucleotide kinase phosphatase;
PP2C: Protein phosphatase 2C;
PPM: serine/threonine-directed phosphatase, metal-dependent;
PPM1D: Protein phosphatase 1D

Consent for publication
Written consent was obtained from the parents.

Ethical approval
This study was approved by the Institutional Review Board Office at King Abdullah International Medical Research Centre (KIMARC) (Study number: RC16/113/R).

Funding
None.

Declaration of conflicting interests
The authors declare that there is no conflict of interests.

Availability of data
The datasets used or analyzed during the work of this case report are available from the corresponding author on judicious request.

Author details

Hind AlMaghthawi[1,2], Marwan Nashabat[1], Majid Alfadhel[1]

1. Genetic Division, Department of Pediatrics, King Abdullah International Medical Research Centre, King Saud bin Abdulaziz University for Health Sciences, King Abdulaziz Medical City, Ministry of National Guard-Health Affairs (NGHA), Riyadh, Saudi Arabia
2. Madina Maternity and Children Hospital, Medina, Saudi Arabia

References

1. Seifried A, Schultz J, Gohla A. Human HAD phosphatases: structure, mechanism, and roles in health and disease. FEBS J 2013; 280(2):549–71. https://doi.org/10.1111/j.1742-4658.2012.08633.x
2. Shi Y. Serine/threonine phosphatases: mechanism through structure. Cell 2009; 139(3):468–84. https://doi.org/10.1016/j.cell.2009.10.006
3. Fiscella M, Zhang H, Fan S, Sakaguchi K, Shen S, Mercer WE, et al. Wip1, a novel human protein phosphatase that is induced in response to ionizing radiation in a p53-dependent manner. Proc Natl Acad Sci USA 1997; 94(12):6048–53. https://doi.org/10.1073/pnas.94.12.6048
4. Lu X, Nguyen TA, Moon SH, Darlington Y, Sommer M, Donehower LA. The type 2C phosphatase Wip1: an oncogenic regulator of tumor suppressor and DNA damage response pathways. Cancer Metastasis Rev 2008; 27(2):123–35. https://doi.org/10.1007/s10555-008-9127-x
5. Kleiblova P, Shaltiel IA, Benada J, Sevcik J, Pechackova S, Pohlreich P, et al. Gain-of-function mutations of PPM1D/Wip1 impair the p53-dependent G1 checkpoint. J Cell Biol 2013; 201(4):511–21. https://doi.org/10.1083/jcb.201210031
6. Swisher EM, Harrell MI, Norquist BM, Walsh T, Brady M, Lee M, et al. Somatic mosaic mutations in PPM1D and TP53 in the blood of women with ovarian carcinoma. JAMA Oncol 2016; 2(3):370–2. https://doi.org/10.1001/jamaoncol.2015.6053
7. Jansen S, Geuer S, Pfundt R, Brough R, Ghongane P, Herkert JC, et al. De novo truncating mutations in the last and penultimate exons of PPM1D cause an intellectual disability syndrome. Am J Hum Genet 2017; 100(4):650–8. https://doi.org/10.1016/j.ajhg.2017.02.005
8. Monies D, Maddirevula S, Kurdi W, Alanazy MH, Alkhalidi H, Al-Owain M, et al. Corrigendum: autozygosity reveals recessive mutations and novel mechanisms in dominant genes: implications in variant interpretation. Genet Med 2018; 19(10):1144–50. https://doi.org/10.1038/gim.2017.22
9. Jilani A, Ramotar D, Slack C, Ong C, Yang XM, Scherer SW, et al. Molecular cloning of the human gene, PNKP, encoding a polynucleotide kinase 3'-phosphatase and evidence for its role in repair of DNA strand breaks caused by oxidative damage. J Biol Chem 1999; 274(34):24176–86. https://doi.org/10.1074/jbc.274.34.24176
10. Shen J, Gilmore EC, Marshall CA, Haddadin M, Reynolds JJ, Eyaid W, et al. Mutations in PNKP cause microcephaly, seizures and defects in DNA repair. Nat Genet 2010; 42(3):245–9. https://doi.org/10.1038/ng.526
11. Poulton C, Oegema R, Heijsman D, Hoogeboom J, Schot R, Stroink H, et al. Progressive cerebellar atrophy and polyneuropathy: expanding the spectrum of PNKP mutations. Neurogenetics 2013; 14(1):43–51. https://doi.org/10.1007/s10048-012-0351-8
12. Berg AT, Berkovic SF, Brodie MJ, Buchhalter J, Cross JH, van Emde Boas W, et al. Revised terminology and concepts for organization of seizures and epilepsies: report of the ILAE Commission on Classification and Terminology, 2005–2009. Epilepsia 2010; 51(4):676–85. https://doi.org/10.1111/j.1528-1167.2010.02522.x
13. Ruark E, Snape K, Humburg P, Loveday C, Bajrami I, Brough R, et al. Mosaic PPM1D mutations are associated with predisposition to breast and ovarian cancer. Nature 2013; 493(7432):406–10. https://doi.org/10.1038/nature11725
14. Hulo N, Bairoch A, Bulliard V, Cerutti L, Cuche BA, de Castro E, et al. The 20 years of PROSITE. Nucleic Acids Res 2008; 36(Database issue):D245–9.