Musallam Said Al-Araimi et al, 2018;1(2):93–97.
https://doi.org/10.24911/JBCGenetics/183-1532358706

CASE REPORT

A new case of *de novo* chromosome 19p13.12 deletion in an Omani girl with multiple congenital anomalies: a first case report from Oman

Musallam Said Al-Araimi[1]*†, Aliya Mahmood Al-Hosni[2]†, Ali Ahmed Al-Yahmadi[3], Salma Mohammed Al-Harasi[4]

ABSTRACT

Background: This report provides a molecular cytogenetic characterization of an Omani girl with 19p13.12 microdeletion and compares her clinical features of global developmental delay (GDD) and multiple congenital anomalies with the gene mutations and disorders associated with this locus.

Case Presentation: The 4-year-old Omani girl was presented to the National Genetic Center with the following clinical features: GDD, hypotonia, multiple congenital anomalies, facial dysmorphism, and skeletal anomalies. Array comparative genomic hybridization identified a 1.913 Mb *de novo* microdeletion in the patient within 19p13.12. The deletion includes 53 genes, of which 35 are Online Mendelian Inheritance in Man (OMIM) genes. The deleted region includes nuclear factor 1 X-type (OMIM #164005), calcium voltage-gated channel subunit alpha1 A (OMIM # 601011), and nucleus accumbens-associated protein 1 (OMIM # 610672) genes which are previously reported to be associated with the presented clinical features.

Conclusion: 19p13.12 microdeletion syndrome is a rare condition for which only one prenatal and five postnatal cases have been reported previously. This case of 19p13.12 microdeletion syndrome is the first case to be reported in Oman as well as in the Gulf Cooperation Council countries and in the Middle East and North Africa.

Keywords: Comparative genomic hybridization, 19p13.12 deletion, dysmorphism.

Introduction

Array comparative genomic hybridization (CGH) has been widely used as a technique that allows identification of molecular changes at the level of DNA bases and the precise identification of chromosome microdeletion. In this report, we present 19p13.12 microdeletion syndrome, a very rare genetic condition, with only one prenatal and five postnatal cases have been reported in the medical literature (1–6).

Case report

We report the case of a 4-year-old girl with 19p13.12 microdeletion syndrome. The patient was born at 38 weeks of gestation to non-consanguineous Omani parents with three healthy children and no family history of dysmorphic or disability syndromes. She was born at 38 weeks of gestation and the pregnancy was uneventful. The girl weighed 3,100 g at birth and her body length was 52 cm, and her head circumference occipital frontal circumference (OFC) measure was 35.5 cm.

At 6 months of age, the girl was examined clinically, her body weight, length, and OFC were measured as 6,500 g, 71 and 44 cm, respectively. Her higher body length and OFC centiles were referred to her family history of tall stature. She was observed to have mild facial dysmorphism including slant of the eyes, low set ears, maxillary hypoplasia, and bitemporal narrowing. She was also observed to have long fingers and toes with

† These authors contributed equally as first authors to this work.
Correspondence to: Musallam Said Al-Araimi
* Clinical Geneticist, Head of The Genetic Counselling & Education Department, The National Genetics Center, Royal Hospital Muscat, Oman.
Email: musallam95@yahoo.com
Full list of author information is available at the end of the article.
Received: 23 March 2018 | **Accepted:** 19 June 2018

© Author(s) open access

This is an open access article distributed in accordance with the Creative Commons Attribution (CC BY 4.0) license: https://creativecommons.org/licenses/by/4.0/)

interdigital skin webs. The girl was then referred to the National Genetic Center, Oman.

At 1 year of age, the girl was found to have global developmental delay (GDD), hypotonia, and language delay. Other facial abnormal features were also observed including long triangular face, frontal bossing, hypertelorism, shallow orbits, prominent eyes, small mouth, inverted lower lip, gum hypertrophy, short philtrum, bluish sclera, brachycephalic, and strabismus (Figure 1).

Also at 1 year of age, she had a radiology test that revealed normal thin long bones, some square-shaped vertebral bodies, and diaphragm eventration.

At 2 years of age on clinical observation, the girl weight was 9,700 g, has body length of 91 cm, and an OFC of 48 cm. She was observed to have arachnodactyly, single palmar crease, interdigital webbing, widely spaced nipples, pectus excavatum, short sternum, and scoliosis. Considering GDD, hypotonia and the dysmorphic features, the girl was then tested by array CGH, where she was diagnosed with 19p13.12 microdeletion syndrome.

At 3 years of age, the girl was observed again at genetic clinic, and her weight, body length, and OFC were 12 kg, 94, and 50 cm, respectively. The patient underwent a radiological investigation in which a computed tomography scan of the brain reported no abnormalities. Brain magnetic resonance imaging was also carried out but showed no abnormalities. A skeletal radiology test was done and showed long, thin, normal-density bones with a prominent bone trabecular pattern, mainly around the hip and knee joints. The pelvis appeared to have a square shape.

We also obtained peripheral blood samples from the patient and her parents. All genetic tests were carried out at the National Genetic Center Laboratory.

Cytogenetic analysis

We cultured peripheral blood in Roswell Park Memorial Institute media (Gibco®, 51800035, Paisley, Scotland, UK), and the cytogenetic analysis was carried out on metaphase chromosomes obtained from phytohemagglutinin (Gibco®, 10576015, Paisley, Scotland, UK) stimulated lymphocyte cultures. Metaphases were stained by Giemsa and chromosome analysis was carried out according to the International System for Human Cytogenetics.

DNA samples

DNA was extracted from whole blood using the Hamilton Genomic STARlet sample processor (Hamilton, Bonaduz, Switzerland), following the manufacturer's instruction. DNA was then quantified using the NanoDrop (ThermoFisher, ND-2000, Grand Island, NY) spectrophotometer.

Array-based

CGHaCGH was carried out using Affymetrix CytoScan HD (ThermoFisher Scientific, Grand Island, NY) and ChAS software V3 (ThermoFisher Scientific, Grand Island, NY). DNA digestion and hybridization were performed according to the manufacturer's instructions. The results were processed into two data sets for chromosome analysis and localization.

Results

Chromosome karyotyping was carried out on peripheral blood samples of the patient and her parents. The results indicated a normal female karyotype (46, XX) for the patient and a normal karyotype in both her parents. In the absence of abnormalities at the G-banding level, array



Figure 1. Photograph of the patient girl at 4 years. *(A) lateral view; (B) frontal view. Dysmorphic facial features are evident, including prominent frontal head, long face, small mouth, low-set outward ears, short philtrum, inverted lower lip, bitemporal narrowing, and hypertelorism.*

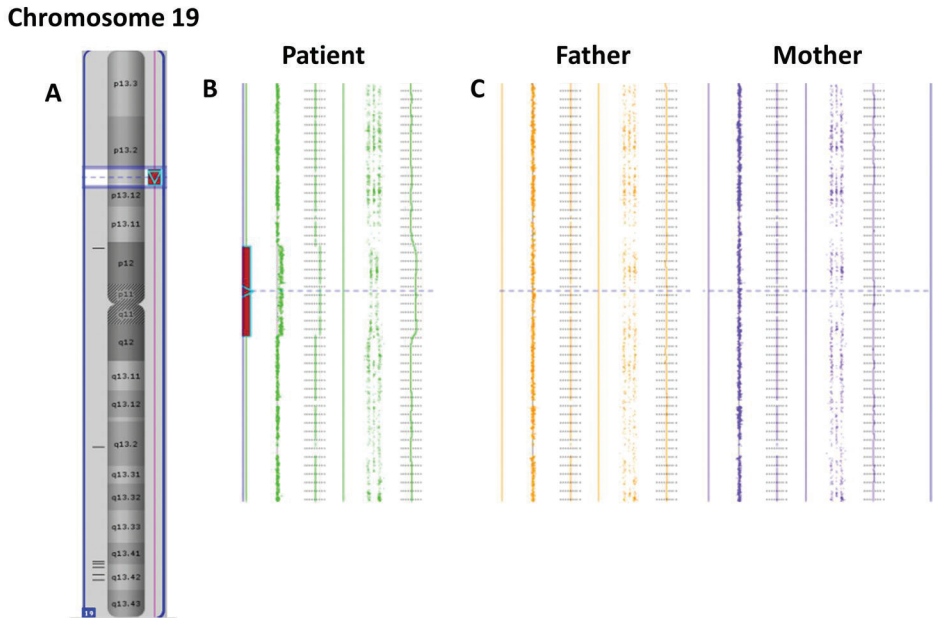

Figure 2. Microdeletion in chromosome 19. *(A) CGH shows a 1.9 Mbp microdeletion at 19p13 (red arrow). (B) The deletion is shown in column B, identified by the red bar. (C) The deletion is not found in the parents (orange: father; purple: mother), and all the genes were detected.*

CGH was carried out, identifying a 1.9 Mbp deletion at 19p13.12 in the patient (Figure 2): arr[hg19] 19p13.12 (12,265,874–14,178,915)x1 dn. The deleted region includes 53 genes, of which 35 are Online Mendelian Inheritance in Man (OMIM) genes. Array CGH was performed on the parents and the results were negative, this confirms that this 19p13.12 deletion in the patient girl is *de novo* since neither of her parents has the deletion (Figure 2C).

The 19p13.12 microdeletion syndrome is a rare genetic condition and has been reported in only a few patients. Engels et al. (3) were the first to describe the syndrome in the Netherlands of a patient with mental retardation and dysmorphic facial features (1), it was described in the USA (5) and Japan (4). The first prenatal case of 19p13.12 microdeletion syndrome was recently reported in France (6).

Our case is the first clinically and genetically identified case of this microdeletion within Oman, Gulf Cooperation Council (GCC) countries, or the Middle East and North Africa (MENA). This particular microdeletion locus contains high gene density, and it was identified by aCGH. There are 53 genes included in this microdeletion, of which 35 are OMIM genes. This microdeletion strongly correlates with the observed severe phenotype.

Chromosome localization to the human genome databases and further analysis of the OMIM gene included in the microdeletion revealed three genes that may be associated with this case: *NFIX* (nuclear factor 1 X-type), *CACNA1A* (calcium voltage-gated channel subunit alpha1 A), and *NACC1* (nucleus accumbens-associated protein 1).

The clinical features of our patient overlap with the previous cases (1,3,5). These features include facial dysmorphism, hypotonia, psychomotor delay, and intellectual disability (Table 1). The shared region of overlap in our patient includes two of the identified OMIM genes: *NFIX* and *CACNA1*.

The gene NFIX is a member of the NF-1 family of transcription factors. The gene expression was analyzed (6) and was expressed prominently in the central and the peripheral nervous system in normal human embryos (gestation day 42) and expressed in the cerebral cortex, the hippocampus, and faintly in the human fetal thalamus at 22 weeks of gestation. Experiments in mice indicate that NFIX1 is highly expressed in the developing mouse brain and is an essential gene for normal skeletal development (7).

Mutation in the *NFIX* gene has been reported to be associated with a Sotos-like phenotype called Malan syndrome (OMIM #614753), in which the affected subject shows unexplained overgrowth, macrocephaly, long narrow face, high forehead, hypotonia, mental retardation, and intellectual disability (7). Another disorder associated with *NFIX* mutation is Marshall-Smith syndrome (OMIM #602535). The affected patient shows accelerated skeletal maturation, failure to thrive, dysmorphic facial features, and scoliosis (7–9).

The *CACNA1A* gene is involved in the voltage-dependent Ca(2+) channel. Mutations in *CACNA1A* have been associated with chronic neurological disorders, such as episodic ataxia and idiopathic generalized epilepsy (10). The *NACC1* gene is a member of the BTB/POZ

Table 1. *Clinical features of patients with 19p13 microdeletion.*

Patient	Engles et al. (3)	Jansen et al. (5)	Bongalia et al. (1) (patient 2)	Present case
Gender	Female	Female	Male	Female
Chromosome region	19p13.12	19p13.12	19p13.12	19p13.12
Deletion size (Mb)	2.1	2.52	1.5	1.9
Position (hg19)	–	13.93–16.36	13.96–14.15	12.26–14.17
Clinical features				
Hypotonia	+	+	+	+
Psychomotor delay	+	+	Moderate	+
Language delay	+	+	+	+
Hearing loss	+	+	Bilateral conductive	–
Skeletal	ND	ND	Scoliosis	Scoliosis, arachnodactyly, bitemporal narrowing
Extremities	ND	+	Clinodactyly and overlapping brachydactyly	–
Facial dysmorphism	+	+	+	+
Seizures	–	–	+	–
Congenital anomalies	+	+	ND	+
Brachycephalic	ND	+	+	+
Philtrum	Long	Long	Long	Short

+, Clinical signs presented; −, Clinical signs absent; ND, not determined. Summary of clinical features and cytogenetic characterization of 19p13 microdeletion patients overlapping the presented case.

family of transcriptional factors. Mutation in the *NACC1* gene (c.892C-R, NM_052876.3) has been associated with the patient's neuro-developmental disorders with epilepsy, cataracts, feeding difficulties, and delayed brain myelination (11).

We suggest that *NFIX* gene defects are the most likely to underlie the clinical presentation in our case. Missense mutations that result in haploinsufficiency or deletions of the entire gene result in Malan syndrome, while dominant negative mutations result in Marshall-Smith syndrome (6).

Conclusion

In conclusion, this report provides information on the rarely identified 19p13.12 microdeletion syndrome, the first to be described in Oman, GCC, and MENA. It adds knowledge to clarify the clinical implementation of the genes involved in the deletion in chromosome 19. This report will contribute to a better understanding of the causes related to 19p13.12 microdeletion syndrome and the genotype-phenotype correlation. However, more clinical studies and functional gene analysis are needed to clarify the phenotypes of this syndrome, along with clarifying the role of other deleted genes.

Acknowledgement
The authors gratefully acknowledge the patient and her family for their contribution. Also, we would like to acknowledge Hiba Al-Mazrooey (Laboratory technician) for her appreciated contribution to this paper.

Declaration of conflicting interests
The authors of this report have no affiliations with or involvement in any organization or entity with any financial interest or non-financial interest in the subject matter or materials discussed in this manuscript.

Consent for publication
A written informed consent was obtained from the parents of the patient at the National Genetics Center in Oman for publication and accompanying images of the case report.

List of Abbreviations
CACNA1A: calcium voltage-gated channel subunit alpha1 A
CGH: Array comparative genomic hybridization
CT: Computed Tomography
DNA: Deoxyribonucleic acid
GCC: Gulf Cooperation Council Countries Middle East and
IPPV: Intermittent positive-pressure ventilation
ISCN: International Systems for human Cytogenetics
Mbp: Mega base pairs
MENA: Middle East and North Africa
MRI: Magnetic Resonance Imaging
NACC1: Nucleus Accumbens-associated protein 1
NFIX: Nuclear Factor I/X
OMIM: Online Mendelian Inheritance in Man North Africa
PHA: Phytohaemagglutinin
RPMI: Roswell Park Memorial Institute

Ethical approval
Ethical approval was sought from the Royal Hospital Research Ethics Committee.

Author details

Musallam Said Al-Araimi[1], Aliya Mahmood Al-Hosni[2], Ali Ahmed Al-Yahmadi[3], Salma Mohammed Al-Harasi[4]

1. Clinical Geneticist, Head of The Genetic Counselling & Education Department, The National Genetics Center, Royal Hospital Muscat, Oman
2. Senior Laboratory Scientist, Molecular Genetics, The National Genetics Center, Royal Hospital Muscat, Oman
3. Laboratory Technician, Molecular Cyto-Genetics, The National Genetics Center, Royal Hospital Muscat, Oman
4. Head of Genetic Lab, Molecular Cyto-Genetics, The National Genetics Center, Royal Hospital Muscat, Oman

REFERENCES

1. Bonaglia MC, Marelli S, Novara F, Commodaro S, Borgatti R, Minardo G, et al. Genotype-phenotype relationship in three cases with overlapping 19p13.12 microdeletions. Eur J Hum Genet 2010; 18(12):1302–9. https://doi.org/10.1038/ejhg.2010.115
2. Dale RC, Grattan-Smith P, Nicholson M, Peters GB. Microdeletions detected using chromosome microarray in children with suspected genetic movement disorders: a single-centre study. Dev Med Child Neurol 2012; 54(7):618–23. https://doi.org/10.1111/j.1469-8749.2012.04287.x
3. Engels H, Brockschmidt A, Hoischen A, Landwehr C, Bosse K, Walldorf C, et al. DNA microarray analysis identifies candidate regions and genes in unexplained mental retardation. Neurology 2007; 68(10):743–50. https://doi.org/10.1212/01.wnl.0000256367.70365.e0
4. Kosaki K, Saito H, Kosaki R, Torii C, Kishi K, Takahashi T. Branchial arch defects and 19p13.12 microdeletion: defining the critical region into a 0.8 M base interval. Am J Med Genet A 2011; 155A(9):2212–4.
5. Jensen DR, Martin DM, Gebarski S, Sahoo T, Brundage EK, Chinault AC, et al. A novel chromosome 19p13.12 deletion in a child with multiple congenital anomalies. Am J Med Genet A 2009; 149A(3):396–402.
6. Huynh MT, Tosca L, Petit F, Martinovic J, Proust A, Bouligand J, et al. First prenatal case of proximal 19p13.12 microdeletion syndrome: New insights and new delineation of the syndrome. Eur J Med Genet 2018; Jun; 61(6):322–328.
7. Malan V, Rajan D, Thomas S, Shaw AC, Louis Dit Picard H, Layet V, et al. Distinct effects of allelic NFIX mutations on nonsense-mediated mRNA decay engender either a Sotos-like or a Marshall-Smith syndrome. Am J Hum Genet 2010; 87(2):189–98. https://doi.org/10.1016/j.ajhg.2010.07.001
8. Driller K, Pagenstecher A, Uhl M, Omran H, Berlis A, Gründer A, et al. Nuclear factor I X deficiency causes brain malformation and severe skeletal defects. Mol Cell Biol 2007; 27(10):3855–67.
9. Yoneda Y, Saitsu H, Touyama M, Makita Y, Miyamoto A, Hamada K, et al. Missense mutations in the DNA-binding/dimerization domain of NFIX cause Sotos-like features. J Hum Genet 2012; 57(3):207–11. https://doi.org/10.1038/jhg.2012.7
10. Chioza B, Wilkie H, Nashef L, Blower J, McCormick D, Sham P, et al. Association between the alpha(1a) calcium channel gene CACNA1A and idiopathic generalized epilepsy. Neurology 2001; 56(9):1245–6. https://doi.org/10.1212/wnl.56.9.1245
11. Schoch K, Meng L, Szelinger S, Bearden DR, Stray-Pedersen A, Busk OL, et al. A recurrent de novo variant in NACC1 causes a syndrome characterized by infantile epilepsy, cataracts, and profound developmental delay. Am J Hum Genet 2017; 100(2):343–51.z