Sadia Tabassum et al, 2018;1(2):98–101.
https://doi.org/10.24911/JBCGenetics/183-1530603908

CASE REPORT

ISCA2 related mitochondrial disorder: a distinct cause of infantile leukodystrophy

Sadia Tabassum[1*†], Ali D Al Otaibi[1†], Rowim Al Mutairi[1], Mohammed Al Mannai[2]

ABSTRACT

Background: Iron–sulfur cluster (ISC) biogenesis is a vital cellular process in the mitochondria. ISC proteins are responsible for essential functions such as glycine cleavage and the formation of lipoic acid, an essential cofactor of respiratory chain complexes. Iron–sulfur cluster assembly2-related mitochondrial disorder (IRMD) is a rare condition described recently and characterized by neurodevelopmental regression, leukodystrophy, optic atrophy, hyperglycinemia, and early death.

Case Presentation: In this report, we present the clinical and radiological features of a subject homozygous for the common founder pathogenic variant; c.229G>A; p.Gly77Ser.

Conclusion: IRMD should be considered in infantile-onset leukodystrophy with optic atrophy and nystagmus. As of now, treatment is only supportive and, therefore, preventive measures should be considered in the families with affected members.

Keywords: Neurodegenerative, infantile leukodystrophy, mitochondrial disorder, respiratory chain.

Introduction

Iron–sulfur cluster (ISC) biogenesis is a vital cellular process in the mitochondria (1,2). Iron–sulfur cluster proteins play a very important role in health and disease (3). It is required to produce various ISC-containing proteins which are present in the nucleus, mitochondria, and cytosol. ISC proteins are responsible for essential functions such as glycine cleavage and the formation of lipoic acid, an essential cofactor of respiratory chain complexes. These proteins are assembled in mitochondria by several steps including specialized targeting components: Iron–sulfur cluster assembly 1(ISCA1), Iron–sulfur cluster assembly 2 (ISCA2), IBA57 Iron–sulfur cluster assembly, and others. *ISCA2* gene encodes an A-type ISC protein involved in the assembly of mitochondrial iron–sulfur cluster (4Fe–4S) which is important for electron transfer and mitochondrial function.

ISCA2-related mitochondrial disorder (IRMD) is a rare condition described recently with most subjects being Arab from Saudi Arabia (4). It is a severe neurodegenerative disorder characterized by neurodevelopmental regression, leukodystrophy, optic atrophy, hyperglycinemia, and early death (4,5). Loss of *ISCA2* has been shown to diminish mitochondrial membrane potential, the mitochondrial network, basal and maximal respiration, and ATP production and to disrupt the 4Fe–4S cluster machinery (6).

In this report, we present the clinical and radiological features of a patient found to be homozygous for the common founder pathogenic variant; c.229G>A; p.Gly77Ser.

Methods

A retrospective chart review was conducted. The CARE guidelines were followed in reporting this case.

Clinical Report

13-month-old boy presented with history of developmental regression since the age of 6 months. He was born at full-term via spontaneous vaginal delivery with a birth weight of 2.8 kg. No pre-, peri-, or post-natal complications. He was discharged home in good

†These two authors contributed equally to be the first author.
Correspondence to: Sadia Tabassum
*Consultant Ped Neurology, National Neuroscience Institute, King Fahad Medical City, Riyadh, Saudi Arabia.
Email: stabassum@kfmc.med.sa
Full list of author information is available at the end of the article.
Received: 23 May 2018 | **Accepted:** 28 June 2018

© Author(s) open access CC BY

This is an open access article distributed in accordance with the Creative Commons Attribution (CC BY 4.0) license: https://creativecommons.org/licenses/by/4.0/)

health. His parents are first degree cousins and he is their first child.

The boy was doing well and with normal development until the age of 6 months when he developed post vaccination febrile illness, and was noted to gradually lose his milestones over the next couple of months. He lost his ability to smile, roll-over, and lost head control. He wasn't fixing or following as he used to and had poor interaction. No nystagmus or any abnormal eye movements were reported by the parents. He started to have feeding difficulties with recurrent choking and aspirations. No abnormal movements or seizures were noted at any time.

On examination, he was normocephalic with no dysmorphism or neurocutaneous stigmata. He had axial hypotonia with appendicular hypertonia brisk reflexes and clonus. Mild contractures of the ankles and elbows were noted. He had respiratory distress while abdomen and cardiovascular examination were unremarkable.

Basic workup including complete blood count and renal and liver function tests were normal. Metabolic workup including ammonia, lactate, tandem mass spectrometry, biotinidase activity, and plasma amino acid was normal. No cerebrospinal fluid (CSF) analysis was done at any time.

Magnetic resonance imaging (MRI) brain obtained at 7-month of age showed confluent T2 hyperintensity involving bilateral cerebral white matter with the tigroid pattern as well as involving corpus callosum, posterior limb of internal capsule, and cerebellar white matter bilaterally. Subcortical U-fibers were relatively spared. Basal ganglia were intact and no definitive diffusion restriction was seen (Figure 1a). Magnetic resonance spectroscopy (MRS) showed elevated choline and lactate peaks (Figure 1b).

Whole exome sequencing showed a homozygous pathogenic variant in *ISCA2* gene c.229G>A; (p.Gly77Ser). The child was subsequently diagnosed with IRMD. He had recurrent chest infections and succumbed to severe pneumonia at 14 months of age.

Discussion

Iron–sulfur cluster (ISC) biogenesis is a vital cellular process in the mitochondria (1,2). They play a very important role in health and diseases (3). *ISCA2* gene mutation is known to cause a neurodegenerative condition, IRMD. Here, we present a child who had the classic presentation of IRMD. IRMD is a relatively new disorder first reported in 2015 (7,8). Since the first report, 20 subjects have been reported, most of them (9) are Arabs from Saudi Arabia (5–9). Also, another gene *IBA57*, involved in iron–sulfur cluster assembly is found to cause severe myopathy with encephalopathy (10).

Infants with IRMD have normal development initially. They present at 3–6 months of age with a triad of progressive neurodevelopmental regression, nystagmus and optic atrophy, and leukodystrophy (5). The regression may be accompanied by irritability and inattention. Axial hypotonia with appendicular hypertonia is observed to develop with the progression of symptoms. The regression continues at variable pace and seizures may develop over the course of the disease.

Due to secondary defects in glycine cleavage, plasma and CSF glycine levels are usually elevated (5,6). On the other hand, elevated lactate levels (serum and CSF) are inconsistent. Respiratory chain enzyme analysis on muscle tissues showed reduced activity of complex II and III (6,9).

Findings on brain MRI include diffuse, bilaterally symmetrical abnormal white matter signal in the cerebral periventricular area, cerebellum, brain stem, and spinal cord. Signal abnormalities in the corpus callosum, internal capsule, midbrain, and middle cerebellar peduncles may also be present. U-fibers and basal ganglia are usually spared. Elevated glycine and lactate peaks on MRS are commonly seen (4).

As this is a relatively newly described disorder, *ISCA2* gene may not be a part of some of the gene panels currently available. Therefore, this entity should be put in consideration when working up an infant presenting with developmental regression and leukodystrophy, especially when this is associated with optic atrophy. All the reported Arab subjects have the founder variant c.229G>A; (p.Gly77Ser) which affects a highly conserved Fe–S domain. The mutation results in the replacement of a glycine with serine at the 77th position. One subject reported from Italy was a compound heterozygote for two variants (c.295delT and c.334A>G) (9).

The differential diagnosis IRMD is broad and includes many disorders with neurodegenerative changes and leukodystrophy such as metachromatic leukodystrophy due to saposin B deficiency (quite common in the region), Leukoencephalopathy with brainstem and spinal cord involvement and lactate elevation, Krabbe disease, vanishing white matter, and others.

There is no curative treatment so far. Affected individuals can only be provided with supportive management and multidisciplinary care. The prognosis is grave with progression to a vegetative state, and eventually death in early childhood.

Conclusion

The key to diagnose IRMD is to correlate the clinical, radiological and biochemical findings. It should be considered in infantile-onset leukodystrophy with optic atrophy and nystagmus. As of now, treatment is only supportive and further studies are needed to understand and identify any targets for future treatment. Preventive management in the form of prenatal testing and preimplantation genetic diagnosis should be considered in the families with affected members.

Acknowledgment
None.

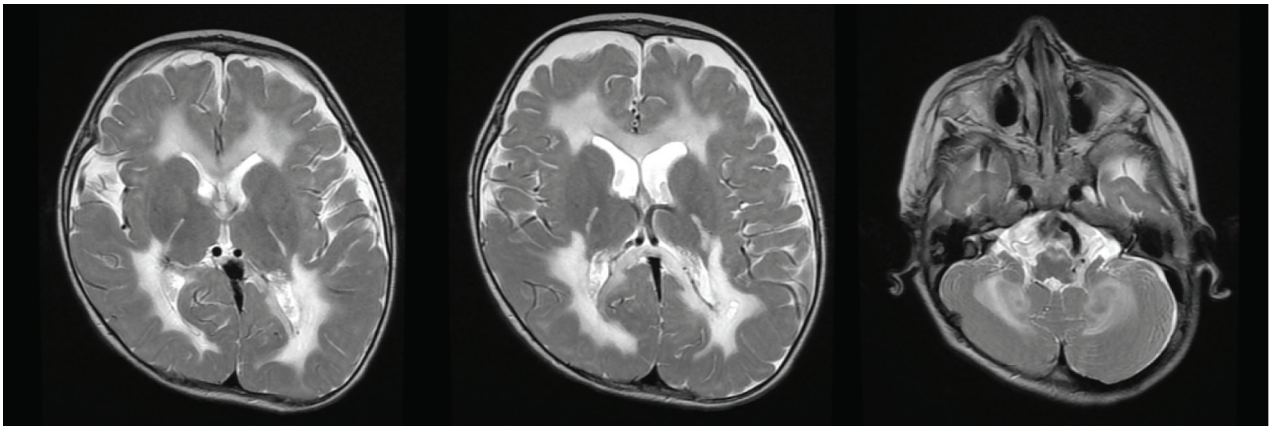

(a)

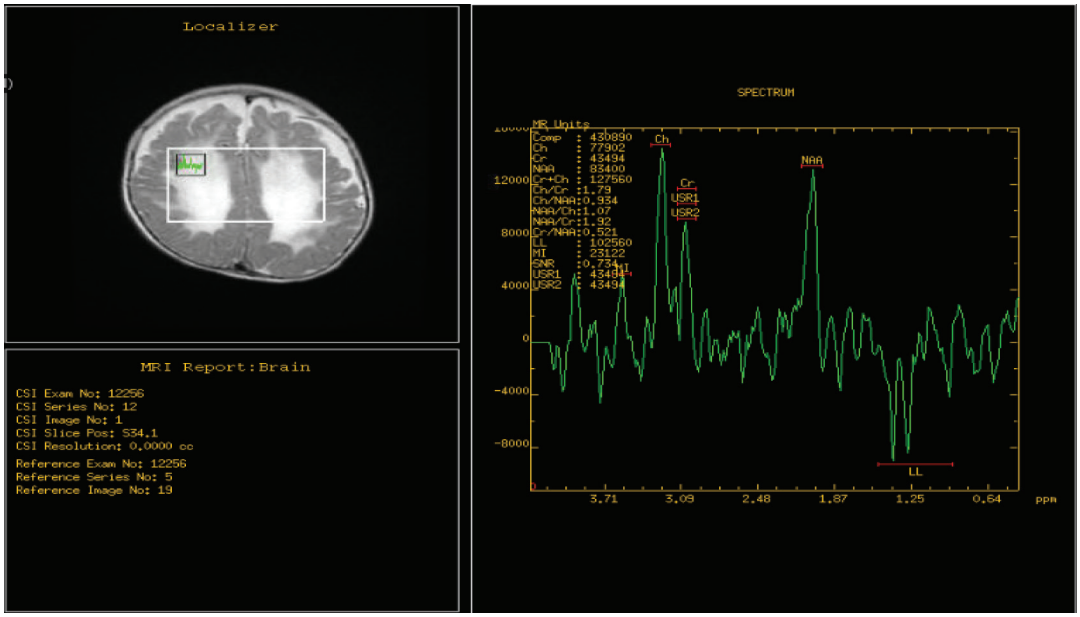

(b)

Figure 1. *(a) MRI brain T2 weighted axial images showing bilateral, symmetrical leukodystrophic changes in cerebral white matter involving corpus callosum, posterior limb of internal capsule and cerebellar white matter. (b) MR spectroscopy showing Lactate and Choline peaks.*

Declaration of conflicting interests

The authors of this report have no affiliations with or involvement in any organization or entity with any financial interest or non-financial interest in the subject matter or materials discussed in this manuscript.

Funding

None.

Consent for publication

Informed consent was obtained from the parents.

Ethical approval

Ethical approval is not required at our institution to publish an anonymous case report.

Author details

Sadia Tabassum[*!1], Ali D Al Otaibi[!1], Rowim Al Mutairi[1], Mohammed Al Mannai[2]

[!]Authors have contributed equally

1. National Neuroscience Institute, King Fahad Medical City, Riyadh, Saudi Arabia
2. Section of Medical Genetics, King Fahad Medical City, Riyadh, Saudi Arabia

References

1. Sheftel AD, Wilbrecht C, Stehling O, Niggemeyer B, Elsässer H-P, Mühlenhoff U, et al. The human mitochondrial ISCA1, ISCA2, and IBA57 proteins are required for [4Fe-4S] protein maturation. Mol Biol Cell 2012; 23(7):1157–66.

2. Lill R, Hoffmann B, Molik S, Pierik AJ, Rietzschel N, Stehling O, et al. The role of mitochondria in cellular iron-sulfur protein biogenesis and iron metabolism. Biochim Biophys Acta 2012; 1823:1491–508. https://doi.org/10.1016/j.bbamcr.2012.05.009
3. Sheftel A, Stehling O, Lill R. Iron-sulfur proteins in health and disease. Trends Endocrinol Metab 2010; 21:302–14. https://doi.org/10.1016/j.tem.2009.12.006
4. Al-Hassnan ZN, Kaya N. ISCA2-related mitochondrial disorder. In: Adam MP, Ardinger HH, Pagon RA, Wallace SE, Bean LJ, Stephens K, et al., editors. GeneReviews® [Internet]. University of Washington, Seattle, WA; 1993. Available from: http://www.ncbi.nlm.nih.gov/books/NBK481904/
5. Alfadhel M, Nashabat M, Alrifai MT, Alshaalan H, Al Mutairi F, Al-Shahrani SA, et al. Further delineation of the phenotypic spectrum of ISCA2 defect: a report of ten new cases. Eur J Paediatr Neurol 2018; 22(1):46–55. https://doi.org/10.1016/j.ejpn.2017.10.003
6. Alaimo JT, Besse A, Alston CL, Pang K, Appadurai V, Samanta M, et al. Loss-of-function mutations in ISCA2 disrupt 4Fe-4S cluster machinery and cause a fatal leukodystrophy with hyperglycinemia and mtDNA depletion. Hum Mutat 2018; 39(4):537–49. https://doi.org/10.1002/humu.23396
7. Alazami AM, Patel N, Shamseldin HE, Anazi S, Al-Dosari MS, Alzahrani F, et al. Accelerating novel candidate gene discovery in neurogenetic disorders via whole-exome sequencing of prescreened multiplex consanguineous families. Cell Rep 2015; 10(2):148–61. https://doi.org/10.1016/j.celrep.2014.12.015
8. Al-Hassnan ZN, Al-Dosary M, Alfadhel M, Faqeih EA, Alsagob M, Kenana R, et al. ISCA2 mutation causes infantile neurodegenerative mitochondrial disorder. J Med Genet 2015; 52(3):186–94.
9. Toldo I, Nosadini M, Boscardin C, Talenti G, Manara R, Lamantea E, et al. Neonatal mitochondrial leukoencephalopathy with brain and spinal involvement and high lactate: expanding the phenotype of ISCA2 gene mutations. Metab Brain Dis 2018; 33(3):805–12. https://doi.org/10.1007/s11011-017-0181-3
10. Bolar NA, Vanlander AV, Wilbrecht C, Van der Aa N, Smet J, De Paepe B, et al. Mutation of the iron-sulfur cluster assembly gene *IBA57* causes severe myopathy and encephalopathy. Hum Mol Genet 2013; 22(13):2590–602. https://doi.org/10.1093/hmg/ddt107