Mai Labani et al. JBC Genetics. 2026;9(1):072-078
DOI: 10.24911/JBCGenetics.11-2782

CASE REPORT

Delayed diagnosis of early-onset N-acetylglutamate synthase deficiency in two related Saudi children

Mai Labani[1], Talal AlAnzi[2], Anwar Almughyiri[3], Moeenaldeen AlSayed[1,4*]

ABSTRACT

Background: N-acetylglutamate synthase deficiency (NAGSD) is the rarest urea cycle disorder and a specifically treatable cause of hyperammonemia. Because tandem mass spectrometry-based newborn screening may be normal, delayed recognition in the presence of hyperammonemia can result in irreversible neurological injury.

Objective: To describe two related Saudi children with early-onset NAGSD and to identify practical diagnostic lessons arising from their delayed diagnoses.

Methods: Clinical presentation, biochemical findings, neuroimaging, molecular results, treatment, and outcomes were reviewed retrospectively.

Results: Case 1 presented at 20 days of age with ammonia greater than 1000 µmol/l and required peritoneal dialysis. Case 2 first presented at 6 weeks with mild hyperammonemia and later developed persistent hyperammonemia of 117–210 µmol/l during an illness-associated encephalopathic episode. Both had elevated glutamine, citrulline within the laboratory reference interval, and normal acylcarnitine profiles. Whole-exome sequencing identified the same homozygous NAGS splice-acceptor variant, NM_153006.3:c.427-2A>T. Carglumic acid was initiated after molecular confirmation in both children, with no further documented clinical hyperammonemic crises; however, both had persistent neurodevelopmental impairment attributable, at least in part, to neurological injury before targeted treatment.

Conclusion: NAGSD should remain in the differential diagnosis of unexplained neonatal or early-infantile hyperammonemia even when citrulline and newborn screening are normal. Prompt evaluation through a standardized hyperammonemia pathway, early consideration of carglumic acid in severe unexplained hyperammonemia, and rapid molecular testing may reduce preventable neurological injury.

Keywords: N-acetylglutamate synthase deficiency, NAGS deficiency; hyperammonemia, urea cycle disorder, carglumic acid, neonatal onset, whole-exome sequencing, neurodevelopmental outcome.

Introduction

The urea cycle is the principal pathway for disposal of nitrogen generated by amino acid catabolism. Carbamoyl phosphate synthetase 1 (CPS1), the first mitochondrial enzyme of the cycle, requires N-acetylglutamate (NAG) as an obligatory allosteric activator. NAG is synthesized by N-acetylglutamate synthase (NAGS); consequently, NAGS deficiency impairs CPS1 activation and produces a biochemical phenotype that closely resembles CPS1 deficiency (Figure 1) (1,2).

NAGSD is an exceptionally rare autosomal recessive urea cycle disorder. Severe disease may present in the neonatal period with poor feeding, vomiting, lethargy, tachypnea, seizures, coma, and marked hyperammonemia, whereas partial deficiency may present later and may be

Correspondence to: Moeenaldeen AlSayed
*College of Medicine, Alfaisal University; Director, MSc Genetic Counseling Program, Alfaisal University; Consultant, Department of Medical Genomics, Center for Genomic Medicine, King Faisal Specialist Hospital and Research Center, Riyadh, Saudi Arabia.
Email: moeen@kfshrc.edu.sa
Full list of author information is available at the end of the article.
Received: 16 August 2026 | **Accepted:** 19 August 2026

OPEN ACCESS
This is an open access article distributed in accordance with the Creative Commons Attribution (CC BY 4.0) license: https://creativecommons.org/licenses/by/4.0/) which permits any use, Share — copy and redistribute the material in any medium or format, Adapt — remix, transform, and build upon the material for any purpose, as long as the authors and the original source are properly cited. © The Author(s).

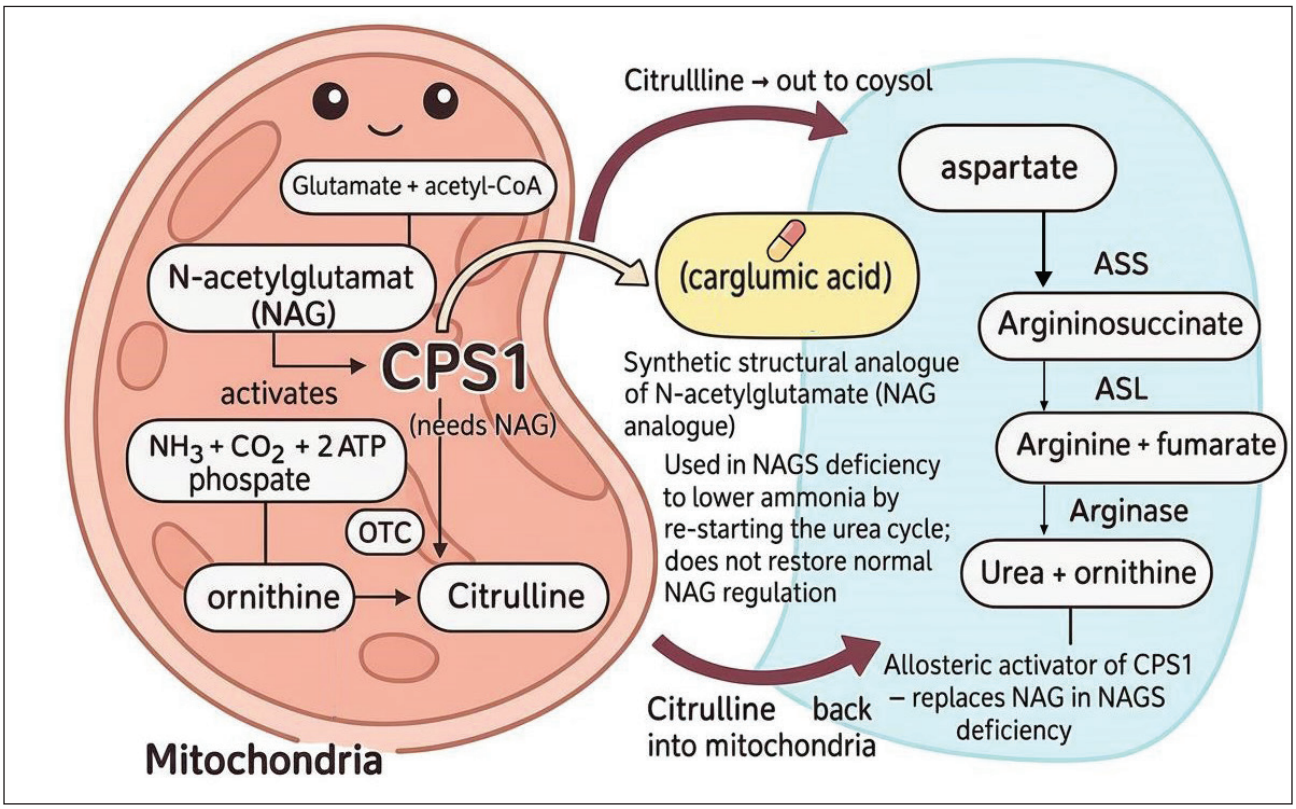

Figure 1. *Role of N-acetylglutamate in CPS1 activation and the mechanism of action of carglumic acid in NAGS deficiency.*

precipitated by catabolic stress (3,4). Unlike other urea cycle disorders, NAGSD can be treated specifically with carglumic acid (N-carbamylglutamate), a stable analog of NAG that activates CPS1 (5,6).

Recognition remains difficult because the biochemical profile is not uniform. Plasma citrulline is often low or undetectable, but it may remain within the reference interval, and routine tandem mass spectrometry-based newborn screening may therefore be unremarkable (7,8). The diagnostic window is clinically important because metabolic control after initiation of carglumic acid can be excellent, whereas neurological injury sustained during untreated hyperammonemia may be irreversible (6, 9).

We report two related Saudi children with early-onset, molecularly confirmed NAGSD who experienced delayed diagnosis and subsequent neurodevelopmental impairment. The report focuses on three practice-relevant lessons: normal citrulline does not exclude a proximal urea cycle disorder; a normal newborn screen does not exclude NAGSD; and a standardized pathway for unexplained hyperammonemia is required to support urgent biochemical sampling, early treatment, and rapid molecular confirmation.

Case Presentations

Case 1

Clinical presentation

A Saudi girl was born at term by spontaneous vaginal delivery to healthy consanguineous parents. At 20 days of age, she developed poor feeding, recurrent vomiting, lethargy, and hypotonia. Plasma ammonia was greater than 1000 µmol/l. She required admission to intensive care and emergency peritoneal dialysis. Seizures developed during the admission and were treated initially with levetiracetam and phenobarbital. Newborn screening had not been performed.

Biochemical and diagnostic evaluation

The initial evaluation was performed at a peripheral hospital. Urine orotic acid analysis was not available, preventing biochemical distinction among NAGSD, CPS1 deficiency, and - without an orotic acid result - ornithine transcarbamylase deficiency. After referral, plasma amino acid analysis showed citrulline 15 µmol/l (reference 12–44 µmol/l), glutamine 837 µmol/l (reference 300–800 µmol/l), and ammonia 66 µmol/l (reference 15–45 µmol/l). The acylcarnitine profile was normal.

Molecular diagnosis and treatment

Clinical whole-exome sequencing identified a pathogenic homozygous splice-acceptor variant in NAGS, NM_153006.3:c.427-2A>T. The diagnosis was established at 2 months of age. Carglumic acid was started after molecular confirmation at 100 mg/kg/day together with a low-protein formula. Protein intake was subsequently liberalized, and she continues carglumic acid in two divided doses. No further documented hyperammonemic crises have occurred since treatment was initiated.

Neurological outcome and imaging

At the most recent assessment at the age of 16 months, she had severe global developmental delay, microcephaly, partial head control, supported sitting, purposeful grasp, cooing, and social smiling. Examination showed upper-limb-predominant hypertonia, brisk deep tendon reflexes, nonsustained clonus, and extensor plantar responses. Seizure control improved on levetiracetam, vigabatrin, and clonazepam, with occasional breakthrough myoclonic jerks. Modified barium swallow demonstrated oral and pharyngeal dysphagia with silent tracheal aspiration.

Brain MRI initially showed diffuse cortical and subcortical white-matter abnormalities with restricted diffusion, predominantly involving the frontal and occipital lobes and corpus callosum. Follow-up imaging demonstrated symmetric T2/FLAIR hyperintensity, gliosis, and volume loss involving the perirolandic, deep, and periventricular white matter, basal ganglia, thalami, cerebellum, and corpus callosum, with diffuse cerebral atrophy and perirolandic ulegyria. These findings were interpreted as sequelae of severe neonatal hyperammonemic encephalopathy.

Family history

The parents are first cousins and have two unaffected children. A related affected first cousin is described as Case 2 and is shown in the pedigree (Figure 2).

Case 2

Clinical presentation

A Saudi boy was born at term after an uncomplicated pregnancy and delivery and was discharged in good health.

At 6 weeks of age, he developed hypoactivity and feeding difficulties, excessive crying, and increased work of breathing without fever or respiratory symptoms. Investigations showed metabolic acidosis, elevated liver enzymes, and ammonia of 66 µmol/l (reference 15–45 µmol/l). The acylcarnitine profile, urine organic acids, and newborn screening were unremarkable. Carbonic anhydrase VA deficiency was initially considered at the local hospital, sodium bicarbonate was started, and whole-exome sequencing was requested. Several arranged follow-up appointments were not attended.

Family history

He is the first cousin of case one. His parents are first cousins; the family history included one previous miscarriage and four healthy siblings.

Recurrent decompensation and biochemical findings

At 6 months of age, he presented with recurrent seizures and impaired consciousness during a febrile upper respiratory tract infection and required pediatric intensive care. Plasma citrulline was 26 µmol/l (reference 12–44 µmol/l), glutamine was 1045 µmol/l (reference 300–800 µmol/l), and ammonia remained elevated at 117–210 µmol/l. The acylcarnitine profile and urine organic acids were normal. A specific urine orotic acid result was not available.

Molecular diagnosis and treatment

At 7 months of age, whole-exome sequencing identified the same pathogenic homozygous NAGS splice-acceptor variant, NM_153006.3:c.427-2A>T. Both parents were heterozygous carriers. Carglumic acid was

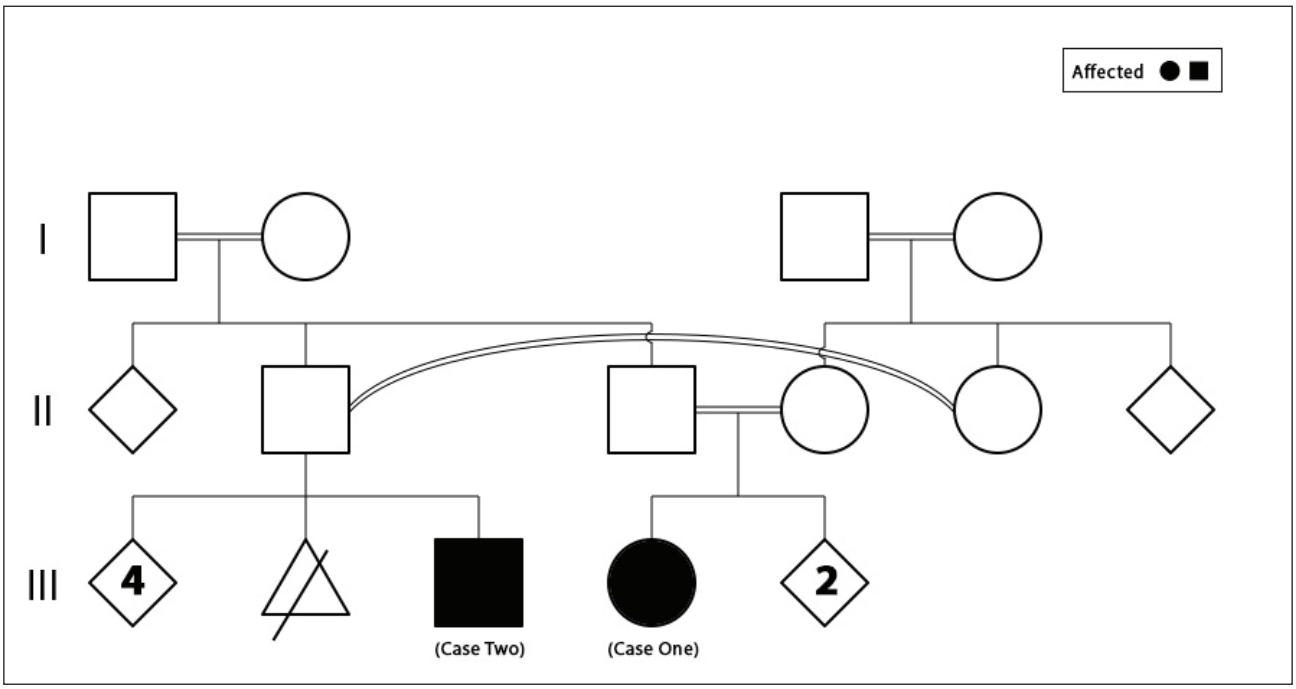

Figure 2. *Three-generation pedigree showing consanguinity and two affected individuals with NAGSD.*

initiated after molecular confirmation at 100 mg/kg/day together with a low-protein formula. Protein restriction was gradually relaxed. No further documented clinical hyperammonemic crises have occurred while he has remained on carglumic acid.

Neurological outcome and imaging

CT of the brain showed no acute intracranial abnormality, and EEG demonstrated a mildly slow background without epileptiform discharges. Brain MRI showed mild diffuse cerebral atrophy, bilateral posterior parietal and occipital periventricular white-matter FLAIR hyperintensities, patchy pontine signal abnormalities, and subtle symmetric medial occipital and temporal FLAIR hyperintensities without diffusion restriction, enhancement, hemorrhage, infarction, or mass effect (Figure 3). At 29 months, he had persistent global developmental delay, most pronounced in receptive and expressive language, together with an ataxic gait and frequent falls. The contribution of cumulative or undocumented hyperammonemia is plausible but cannot be established retrospectively, and other factors may also have contributed.

Discussion

NAGSD is the rarest defect of the urea cycle, but it is also the disorder for which a highly specific pharmacological treatment is available. The two cases illustrate the contrast between good metabolic control after carglumic acid and persistent neurological disability after diagnostic delay. Their principal contribution is therefore a clinically relevant demonstration of how NAGSD may be missed when citrulline and newborn screening are normal, complete proximal UCD testing is unavailable, and a standardized hyperammonemia pathway is not implemented.

NAGSD and CPS1 deficiency share hyperammonemia, elevated glutamine, low or low-normal citrulline, and usually low or absent urinary orotic acid (7). However, the 2024 multicenter case series reported citrulline within the reference interval in several genetically confirmed patients and mild orotic acid elevation in some, underscoring that neither normal citrulline nor a mildly atypical orotic acid result excludes NAGSD.[9] Both children in the present report had citrulline values within the laboratory reference interval.

Neurological outcome in UCDs is influenced by peak ammonia concentration, duration of exposure, recurrence, and timeliness of treatment. Case 1 experienced profound neonatal hyperammonemia and developed severe structural brain injury and global developmental delay. In Case 2, the first documented ammonia value was only mildly elevated, but a later episode included persistent concentrations of 117–210 µmol/l, seizures, impaired consciousness, and MRI abnormalities.

The Tanzanian case described by Thaver et al. similarly presented with severe neonatal hyperammonemic encephalopathy in a consanguineous family, but carglumic acid was unavailable and the infant died at 49 days (15). Reports of presymptomatic or very early treatment in affected families show substantially better outcomes, supporting the importance of family history, rapid diagnosis, and immediate access to therapy.[11] Firm genotype–phenotype correlations remain difficult because pathogenic variants are heterogeneous and published case numbers remain small (6,8).

It is possible that the patient may have experienced undocumented metabolic decompensations, which may have cumulatively contributed to neurotoxicity and global developmental delay. Chronic low-grade hyperammonemia has been reported to adversely affect cerebral function and neurodevelopment (10,14).

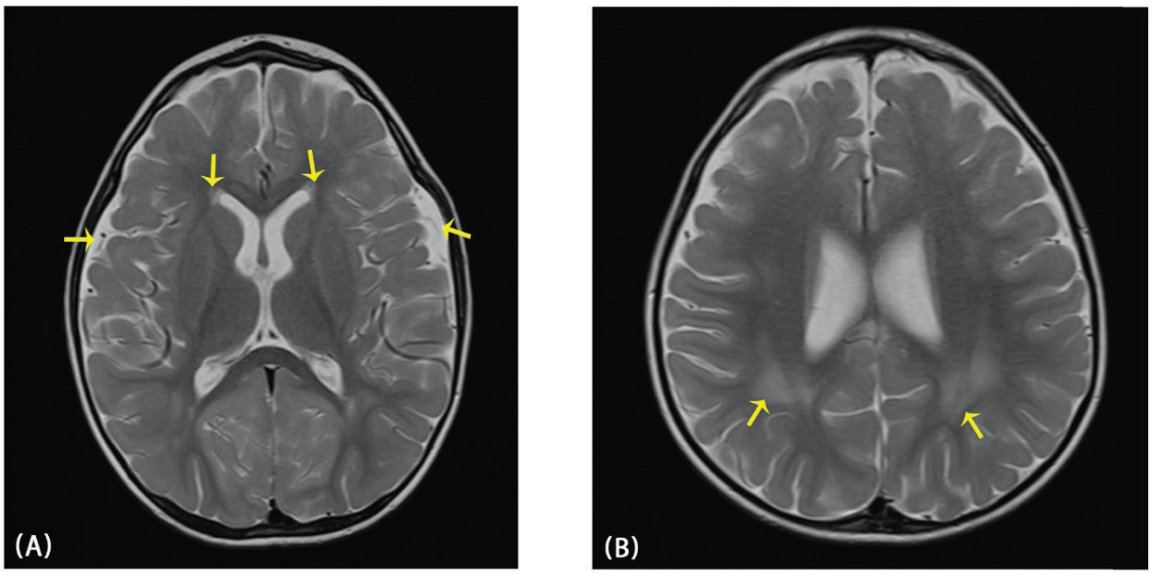

Figure 3. *Brain MRI findings in Case 2. (A) Axial T2-weighted image showing mild diffuse cerebral atrophy with prominence of the extra-axial CSF spaces and ventricular system. (B) Axial FLAIR image showing bilateral posterior periventricular signal abnormalities.*

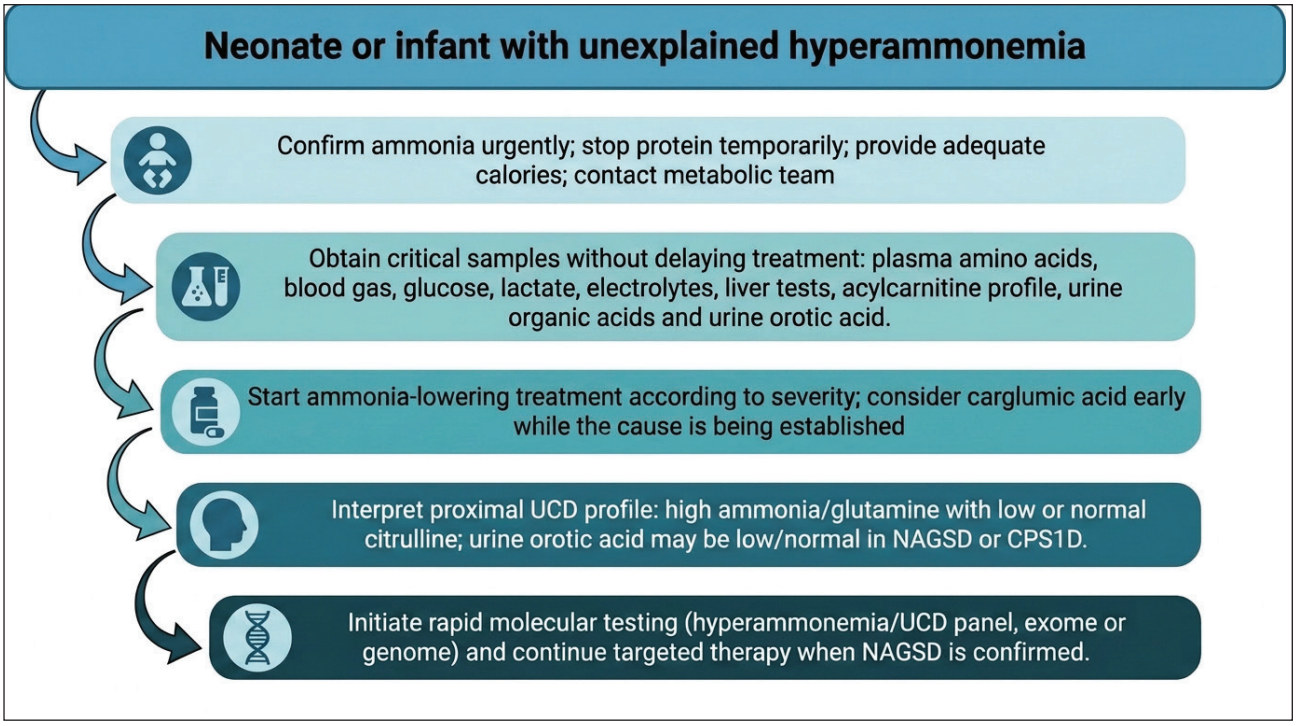

Figure 4. *Author-created diagnostic and initial-management pathway for unexplained neonatal or early infantile hyperammonemia. This pathway is based on published regional and international guidance (including Häberle et al. 2012; Häberle et al. 2019; Alfadhel et al. 2016) and is not reproduced or adapted from any single published figure (8,12,16).*

Table 1. *Comparison of the two patients.*

Characteristic	Case 1	Case 2
Sex	Female	Male
Age at first presentation	20 days	6 weeks; major recurrent decompensation at 6 months
Age at molecular diagnosis	2 months	7 months
Peak documented ammonia	>1000 µmol/l	210 µmol/l
Citrulline	15 µmol/l (reference 12–44)	26 µmol/l (reference 12–44)
Glutamine	837 µmol/l (reference 300–800)	1045 µmol/l (reference 300–800)
Urine orotic acid	Not performed	Specific result not available
Molecular finding	Homozygous NM_153006.3(NAGS):c.427-2A>T	Homozygous NM_153006.3(NAGS):c.427-2A>T
Treatment	Peritoneal dialysis acutely; carglumic acid 100 mg/kg/day after diagnosis; initial protein restriction later liberalized	Carglumic acid 100 mg/kg/day after diagnosis; initial protein restriction later liberalized
Metabolic response	No further documented hyperammonemic crises after carglumic acid	No further documented clinical hyperammonemic crises after carglumic acid
Current neurological outcome	Severe global developmental delay, microcephaly, spasticity, epilepsy, and dysphagia with silent aspiration	Global developmental delay, marked speech-language impairment, ataxic gait, and frequent falls

Carglumic acid replaces the missing NAG signal and can normalize ureagenesis in NAGSD. Current UCD guidance supports its early use in severe unexplained hyperammonemia while the diagnosis is being established, followed by long-term continuation when NAGSD is confirmed (12,13). Both children in this report started carglumic acid only after molecular confirmation and subsequently had no further documented clinical hyperammonemic crises.

Long-term protein restriction is often unnecessary once stable metabolic control is achieved, although individualized dietary monitoring, emergency illness plans, and contingency plans for interrupted medication access remain essential. The 2024 case series emphasized

that treatment interruption can precipitate recurrent hyperammonemia and that the maximum safe protein intake has not been defined (9).

These cases support a systems-based response to neonatal and infantile hyperammonemia. Confirmation of ammonia, critical biochemical sampling, metabolic consultation, ammonia-lowering treatment, consideration of carglumic acid, and rapid molecular testing should proceed in parallel rather than sequentially. The author-created pathway in Figure 4 summarizes this approach and is based on regional and international guidance (8,12,16).

Conclusion

NAGSD should be considered in any neonate, young infant, and less commonly, adults with unexplained hyperammonemia, including those with citrulline within the reference interval or a normal newborn screen. In these two children, carglumic acid initiated after molecular diagnosis was followed by sustained clinical metabolic stability, but neurological impairment established before targeted treatment persisted. A standardized hyperammonemia pathway, urgent metabolic input, early consideration of carglumic acid in severe unexplained cases, and rapid molecular testing are practical measures that may reduce preventable diagnostic delay and neurological injury .

List of Abbreviations

ASL	Argininosuccinate lyase
ASS	Argininosuccinate synthetase
ATP	Adenosine triphosphate
CPS1	Carbamoyl phosphate synthetase 1
CPS1D	Carbamoyl phosphate synthetase 1 deficiency
CSF	Cerebrospinal fluid
CT	Computed tomography
EEG	Electroencephalography
FLAIR	Fluid-attenuated inversion recovery
IRB	Institutional Review Board
MRI	Magnetic resonance imaging
NAG	N-acetylglutamate
NAGS	N-acetylglutamate synthase
NAGSD	N-acetylglutamate synthase deficiency
OTC	Ornithine transcarbamylase
UCD	Urea cycle disorder

Conflict of interest

The authors of this article have no affiliations with or involvement in any organization or entity with any financial interest or nonfinancial interest in the subject matter or materials discussed in this manuscript.

Funding

No funding was received for this work.

Consent to participate

In accordance with institutional policy at King Faisal Specialist Hospital and Research Center, IRB approval is not required for case reports involving three or fewer patients when no identifiable patient information is disclosed.

Ethical approval

In accordance with institutional policy at King Faisal Specialist Hospital and Research Center, IRB approval is not required for case reports involving three or fewer patients when no identifiable patient information is disclosed.

Author contributions

Mai Labani: data collection, clinical review, and manuscript drafting. Talal AlAnzi: clinical care, data contribution, and review. Anwar Almughyiri reviewed the radiological images and summarized the findings. Moeenaldeen AlSayed: conceptualization, supervision, clinical interpretation, and manuscript revision. All authors reviewed and approved the final manuscript.

Mai Labani[1], Talal AlAnzi[2], Anwar Almughyiri3, Moeenaldeen AlSayed[1,4]

1. Department of Medical Genomics, King Faisal Specialist Hospital and Research Center, Riyadh, Saudi Arabia
2. Women and Children Department, Johns Hopkins Aramco Healthcare, Dhahran, Saudi Arabia
3. Department of Radiology, King Faisal Specialist Hospital and Research Center, Riyadh, Saudi Arabia
4. College of Medicine, Alfaisal University, Riyadh, Saudi Arabia

References

1. Wijburg FA, Nassogne MC. Disorders of the urea cycle and related enzymes. In: Saudubray JM, van den Berghe G, Walter JH, editors. Inborn metabolic diseases: diagnosis and treatment. Berlin: Springer; 2012. p. 297–310.
2. Caldovic L, Tuchman M. N-acetylglutamate and its changing role through evolution. Biochem J. 2003;372(Pt 2):279–90. https://doi.org/10.1042/BJ20030002.
3. Ah Mew N, Simpson KL, Gropman AL, Ah Mew N, Adam MP, Bick S, et al. Urea cycle disorders overview. GeneReviews®. Updated June 22, 2017.
4. El Kaabi EH, El-Hattab AW. N-acetylglutamate synthase deficiency: novel mutation associated with neonatal presentation and literature review of molecular and phenotypic spectra. Mol Genet Metab Rep. 2016;8:94–98. https://doi.org/10.1016/j.ymgmr.2016.07.005.
5. Elpeleg O, Shaag A, Ben-Shalom E, Schmid T, Bachmann C. N-acetylglutamate synthase deficiency and the treatment of hyperammonemic encephalopathy. Ann Neurol. 2002;52(6):845–9. https://doi.org/10.1002/ana.10406.
6. Kenneson A, Singh RH. Presentation and management of N-acetylglutamate synthase deficiency: a review of the literature. Orphanet J Rare Dis. 2020;15:279. https://doi.org/10.1186/s13023-020-01560-z.
7. Ah Mew N, Caldovic L. N-acetylglutamate synthase deficiency: an insight into the genetics, epidemiology, pathophysiology, and treatment. Appl Clin Genet. 2011;4:127–35. https://doi.org/10.2147/TACG.S12702.
8. Häberle J, Burlina A, Chakrapani A, Dixon M, Karall D, Lindner M, et al. Suggested guidelines for the diagnosis and management of urea cycle disorders: first revision. J Inherit Metab Dis. 2019;42(6):1192–1230. https://doi.org/10.1002/jimd.12100.
9. Singh RH, Bourdages MH, Kurtz A, Macloed E, Norman C, Ratko S, et al. The efficacy of carbamylglutamate impacts the nutritional management of patients with

N-acetylglutamate synthase deficiency. Orphanet J Rare Dis. 2024;19:168. https://doi.org/10.1186/s13023-024-03167-0.

10. Waisbren SE, Cuthbertson D, Burgard P, Holbert A, McCarter R, Cederbaum S; Members of the Urea Cycle Disorders Consortium. Biochemical markers and neuropsychological functioning in distal urea cycle disorders. J Inherit Metab Dis. 2018;41(4):657—67. https://doi.org/ 10.1007/s10545-017-0132-5. Epub 2018 Feb 8. PMID: 29423830; PMCID: PMC6041144..
11. Peoc'h K, Damaj L, Pelletier R, Lefevre C, Dubourg C, Christine-Dubourg D, et al. Early care of N-acetyl glutamate synthase deficiency in three infants from an inbred family. Mol Genet Metab Rep. 2020;22:100558. https://doi.org/10.1016/j.ymgmr.2019.100558.
12. Häberle J, Boddaert N, Burlina A, Chakrapani A, Dixon M, Karall D, et al. Suggested guidelines for the diagnosis and management of urea cycle disorders. Orphanet J Rare Dis. 2012;7:32. https://doi.org/10.1186/1750-1172-7-32.
13. Häberle J. Carglumic acid for the treatment of N-acetylglutamate synthase deficiency and acute hyperammonemia. Expert Rev Endocrinol Metab. 2012;7(3):263–71. https://doi.org/10.1586/eem.12.17.
14. Gropman AL. Brain imaging in urea cycle disorders. Mol Genet Metab. 2010;100(Suppl 1):S20–S30. https://doi.org/ 10.1016/j.ymgme.2010.01.017.
15. Thaver S, Ebrahim M, Noorani M, Alimohamed ZM, Edward K, Furia F, et al. Diagnostic and management challenges of a case of N-acetylglutamate synthase deficiency in a resource-limited healthcare setting in Tanzania: a case report. BMC Pediatr. 2026;26:86. https://doi.org/10.1186/s12887-025-06449-z.
16. Alfadhel M, Mutairi FA, Makhseed N, Jasmi FA, Al-Thihli, Al-Jishi E, et al. Guidelines for acute management of hyperammonemia in the Middle East region. Ther Clin Risk Manag. 2016;12:479–87. https://doi.org/10.2147/TCRM.S93144.